

5th Congress of the European Academy of Neurology

Oslo, Norway, June 29 - July 2, 2019

Hands-on Course 15

**Bedside examination of the vestibular and ocular motor
system (Level 2)**

**How to diagnose and treat benign paroxysmal
positional vertigo**

Dominik Straumann + Thomas Brandt
Zurich, Switzerland + Munich, Germany

Email: dominik.straumann@usz.ch

Email: thomas.brandt@med.uni-muenchen.de

Bedside provocation and liberation maneuvers in patients with benign paroxysmal positional vertigo (BPPV)

Dominik Straumann (1), Thomas Brandt (2)

1: Department of Neurology, University Hospital Zurich and University of Zurich, Switzerland

2: Institute of Clinical Neurosciences, University Hospital Munich Großhadern, Ludwig-Maximilians-University Munich, Germany

Contacts:

Dominik.Straumann@usz.ch, Thomas.Brandt@med.uni-muenchen.de

Introduction

Most patients with BPPV can be treated successfully with the appropriate liberation maneuver for an affected semicircular canal. Therefore, every patient with dizziness or imbalance, even in the absence of typical complaints of BPPV, should undergo provocation maneuvers to detect BPPV due to canalolithiasis or cupulolithiasis.

Provocation maneuvers

We suggest performing two provocation maneuvers on each side: The Dix-Hallpike maneuver and the supine-roll maneuver. If all maneuvers are negative, they should be repeated at least once during the same visit. After all, it is not rare that positional vertigo and nystagmus is only elicited with the second execution of a specific provocation maneuver.

Dix–Hallpike maneuver

This provocation maneuver detects canalolithiasis of a posterior semicircular canal (Dix & Hallpike 1952). The head of the sitting patient is rotated along the yaw plane 45° to the right or left. The patient is then guided from the sitting position to the head-hanging position, while the head is kept in the previous yaw position relative to the trunk (Fig. 1, row 1). Typically, in the presence of a posterior canalolithiasis ipsilateral to the head yaw position, nystagmus occurs after a few seconds, is upbeat, lasts a few seconds (no more than 60 seconds) and shows both a vertical and a torsional component. A positional nystagmus beating downward,

with or without a torsional component, may be central (unmasked cerebellar downbeat nystagmus) or due to contralateral anterior canalolithiasis. Expressed in space-fixed coordinates, upbeat nystagmus in the head-hanging position is geotropic, i.e., directed toward the earth, and downbeat nystagmus is apogeotropic.

Supine-roll maneuver

This provocation maneuver detects a canalolithiasis or cupulolithiasis of a horizontal semicircular canal (McClure, 1985; Pagnini et al., 1989). The patient is asked to lie in the supine position, whereby the headboard is raised by about 20–30°. Then, the head is quickly rotated along its yaw plane into the right-ear-down or left-ear-down position (or as far as neck yaw mobility allows). This head rotation is a roll movement expressed in space-fixed coordinates, hence the term supine-roll maneuver. In case of a horizontal canalolithiasis or cupulolithiasis, horizontal nystagmus, usually with a torsional component, occurs, whereby the nystagmus beats either geotropically or apogeotropically in both ear-down positions, i.e., the nystagmus changes its direction relative to the head depending on the head roll position. Many times, horizontal positional nystagmus appears without latency. An apogeotropic pattern together with persistence of nystagmus points to a cupulolithiasis (Baloh et al. 1995).

Liberation maneuvers

If a provocation maneuver elicits positional vertigo and nystagmus, we continue with the appropriate liberation maneuver and skip the pending provocations maneuvers. Multiple liberation maneuvers have been described for canalolithiasis or cupulolithiasis of every semicircular canal (Brandt et al. 2013). For practical purposes, neurologists not specialized in neuro-otology can concentrate on liberation maneuvers for the posterior and horizontal semicircular canals, since the anterior semicircular canal is only rarely affected (Korres et al. 2002). The rationale of every liberation maneuver is to remove detritus out of the affected semicircular canal, hereby taking into account that one of the two exits of every semicircular canal is blocked by a cupula.

To liberate the posterior semicircular canals from detritus, both the Epley maneuver and the Semont maneuver are widely used and similarly effective. To liberate the horizontal semicircular canals from detritus, both the Gufoni maneuver and the Lempert maneuver are presently in vogue.

Epley maneuver

This liberation maneuver (Fig. 1) removes detritus from the posterior semicircular canal (Epley 1992). Hereby the head is rotated from the Dix-Hallpike head-hanging position (Fig. 1, row 2), in which positional vertigo and nystagmus occurred, by two steps of 90° to the other side (Fig. 1, rows 3a & 3b). To enable the second head rotation, the body is rolled to the side position. Finally, the patient is brought to the sitting position, whereby the head keeps its

previous 45° yaw position (Fig. 1, row 4). Only when the patient sits upright, the head may return to the neutral position. In all four Epley positions, the head is kept still for at least 30 seconds or as long as the nystagmus lasts.

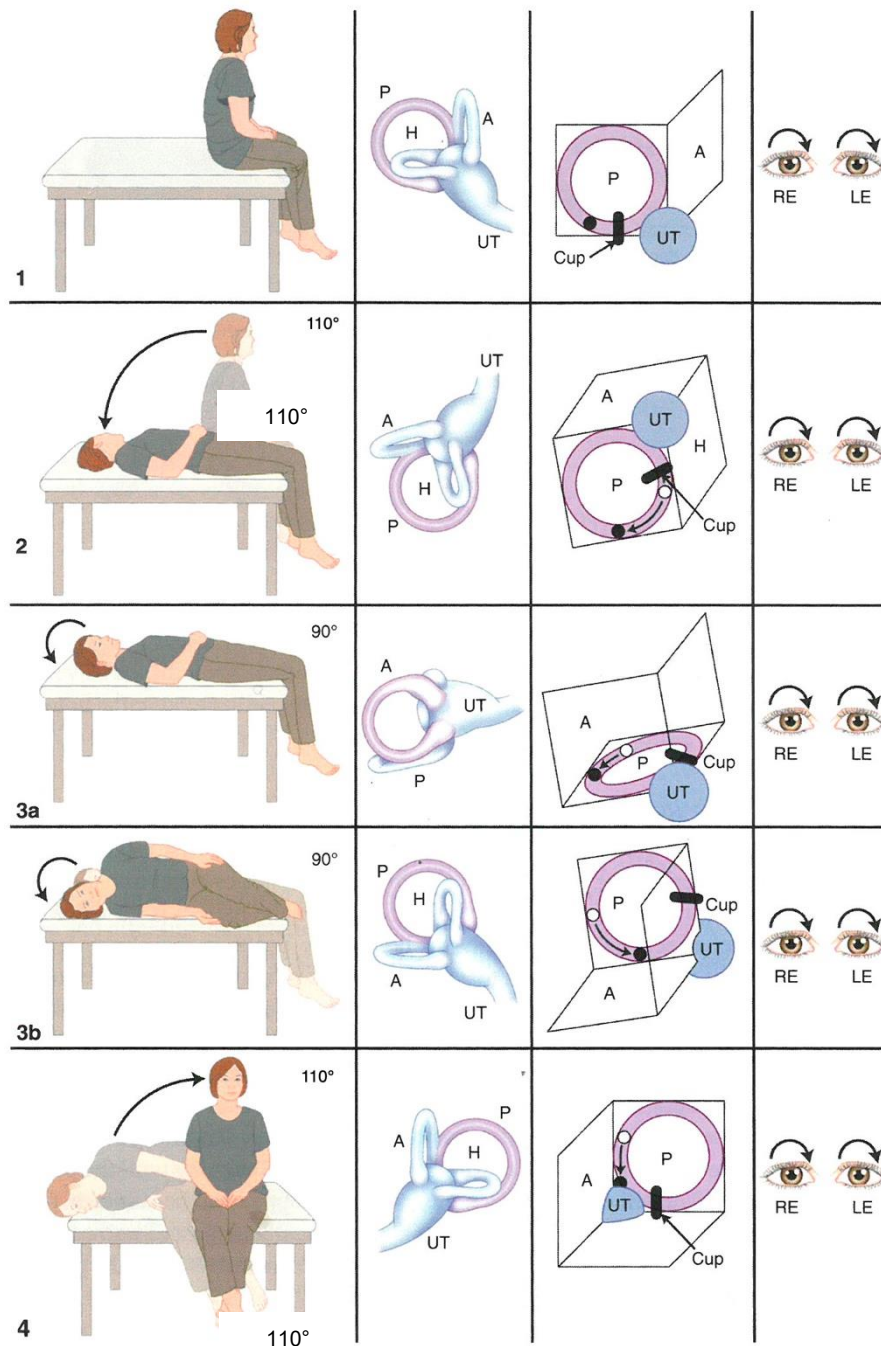


Figure 1: Schematic drawing of the Epley liberation maneuver in a patient with typical benign paroxysmal positioning vertigo of the left ear (adapted from Brandt et al. 1994). The first movement (row 2) corresponds to the Dix-Hallpike provocation maneuver for the left side. Panels from left to right: position of body and head, position of labyrinth in space, position and movement of detritus in the posterior canal (which causes cupula deflection), and the direction of the vertical-torsional nystagmus. The detritus is depicted as an open circle within the canal; a black circle represents the final resting position of the detritus. A, P, H: anterior, posterior, horizontal semicircular canals; Cup: cupula; UT: utricular cavity; RE: right eye; LE: left eye.

Semont maneuver

This liberation maneuver (Fig. 2) also removes detritus from the posterior semicircular canal (Semont et al. 1988). Contrary to the Epley maneuver, the Semont maneuver cannot be performed as a continuation of a positive Dix-Hallpike provocation maneuver. Rather, the patient is seated on the side of the examination table (Fig. 2, row 1) and then rotates the head along the yaw plane 45° to the unaffected side. The patient is then guided to lie down on the affected side but keeping the previous yaw position of the head (Fig. 2, row 2). For better therapeutic success, the head should hang below the horizontal by at least 20° (Obrist et al. 2016). After resting in this side position for 1-2 minutes, the patient is brought to lie on the unaffected side by rotating the trunk along the roll plane by 180° , bypassing the upright position, whereby the previous 45° yaw position of the head is still being maintained (Fig. 2, row 3). The velocity of this movement may not be critical, but the head, which is now obliquely pointing down, better hangs below the horizontal by at least 20° (Obrist et al. 2016). After 1-2 minutes in this side position, the patient is moved to the initial upright sitting position, in which the head may rotate back to its neutral position (Fig. 2, row 4).

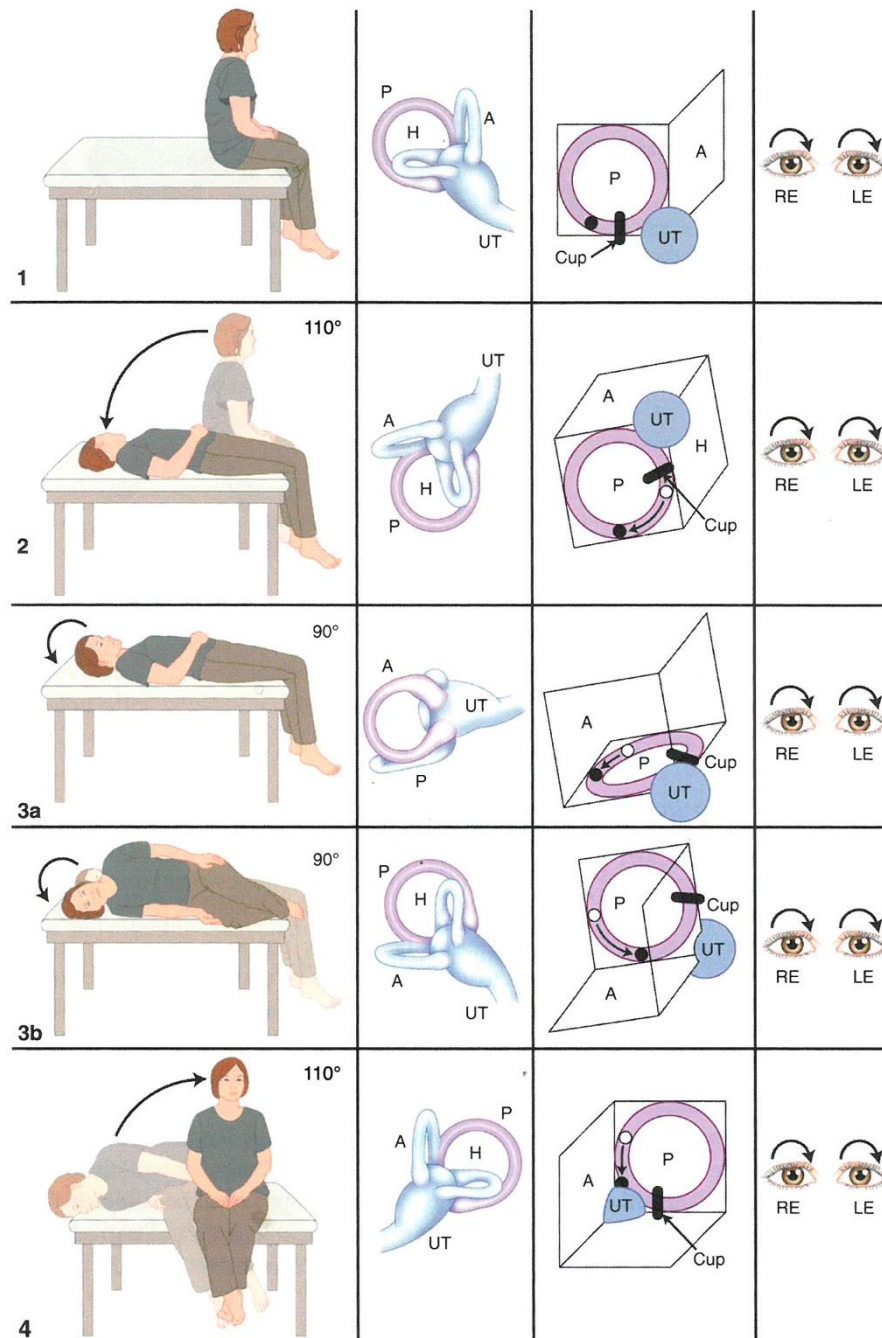


Figure 2: Schematic drawing of the Semont liberation maneuver in a patient with typical benign paroxysmal positioning vertigo of the left ear (adapted from Brandt et al. 1994). Panels from left to right: position of body and head, position of labyrinth in space, position and movement of detritus in the posterior canal (which causes cupula deflection), and the direction of the vertical-torsional nystagmus. The detritus is depicted as an open circle within the canal; a black circle represents the final resting position of the detritus. A, P, H: anterior, posterior, horizontal semicircular canals; Cup: cupula; UT: utricular cavity; RE: right eye; LE: left eye.

Gufoni maneuver

This liberation maneuver (Fig. 3) removes detritus from the horizontal semicircular canal (Gufoni et al. 1998). There are two versions of the Gufoni liberation maneuver: one for the geotropic variant and one for the apogeotropic variant of horizontal BPPV. In both versions,

the patient is seated upright on the side of the examination table and is first brought to the side position, at which there was less horizontal positional nystagmus during the supine-roll provocation maneuver (Fig. 3, row b). In case of the geotropic variant, this is the side of the unaffected ear; in case of the apogeotropic variant, this is the side of the affected ear. After 20 seconds in this side position, the head is rotated along the yaw plane 45° down (Fig. 3, row c) for the geotropic variant (Casani et al. 2002) or 45° up for the apogeotropic variant (Appiani et al. 2005). After 1–2 minutes in this position, the patient is brought back to the sitting position, in which the head may rotate back to the neutral position. In some cases, the Gufoni head-up liberation maneuver converts the apogeotropic variant of horizontal BPPV into the geotropic variant. If this occurs, one should perform the Gufoni head-down liberation maneuver to the other side during the same visit.

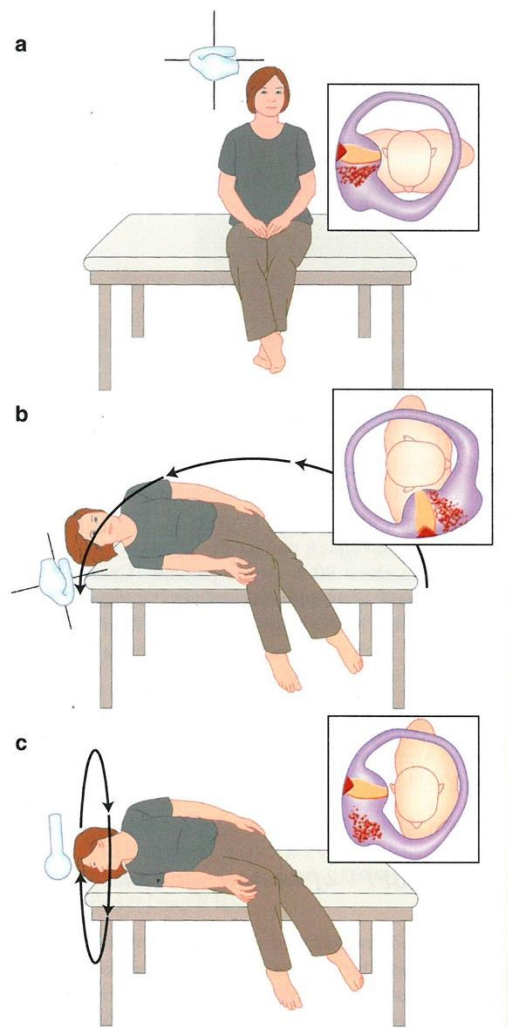


Figure 3: Schematic drawing of the Gufoni liberation maneuver for treating the geotropic variant of horizontal semicircular canal BPPV (adapted from Casani et al. 2002, which is modified from Gufoni et al. 1998). Inset: Position of head, trunk and horizontal semicircular canal (enlarged). A downward movement of the head by 45° is sufficient (row c). In case of an apogeotropic variant, the head is moved 45° upward.

Lempert maneuver

This liberation maneuver also removes detritus from the horizontal semicircular canal in case of a geotropic variant (Lempert 1994): The patient is rolled from the supine position by 270° in the direction at which there was less horizontal positional nystagmus during the supine-roll provocation maneuver, which is the side of the unaffected ear. Rotations are in steps of 90°. At each position, the patient rests for 30–60 seconds. From the last position, which is the affected side, the patient is brought up to the sitting position. The Lempert liberation maneuver is also called barbecue maneuver for its similarity to rotations on the grill. To roll the patients in 90° steps by 450° or more in the direction of the unaffected ear maybe more effective than by 270° only (Waespe 1997, Fife 1998). In some cases, the Lempert liberation maneuver by 270° or by 450° may also be successful for the apogeotropic variant of BPPV, whereby the body is again rolled in the direction at which there was less horizontal positional nystagmus during the supine-roll provocation maneuver (personal observation).

Comments on the liberation maneuvers

- Vibration of the mastoid bone on the affected side before and during liberation maneuvers may facilitate the movement of the detritus within a semicircular canal (Epley 2001). Alternatively, mastoid percussion (fingers, reflex hammer) can be applied. Rapid head shaking in the sitting position (e.g. 3 Hz for 15 seconds, head pitched forward by about 30°) may substitute the Gufoni liberation maneuver for the apogeotropic variant of horizontal BPPV (Kim et al. 2011). Prolonged lying on the unaffected ear has shown to be a valid alternative for the treatment of the geotropic variant of horizontal BPPV (Vannucchi et al. 1997).
- Bilateral BPPV is difficult to treat during a single visit, because a liberation maneuver on one side may undo the previous liberation maneuver on the other side. We therefore suggest treating one side only during the first visit and the other side one day later.
- Immediately after a successful liberation maneuver, patients may sometimes experience a falling sensation, which is possibly due to detritus falling on the utricular membrane (Uneri 2005). Imbalance for hours or even days after a successful liberation maneuver is common (Seok et al. 2008).
- The success of a liberation maneuver may be confirmed by repetition of the corresponding provocation maneuver, provided the patient is not too much nauseated. If positional vertigo and nystagmus persists, the liberation maneuver should be repeated during the same or at a follow-up visit. If the liberation maneuvers remain unsuccessful over a period of two weeks, we recommend ordering cranial MRI to exclude a central cause of positional vertigo.

- After a successful liberation maneuver, the patient should avoid high-acceleration head movements (e.g. jogging, jumping) and head positions below the horizontal (e.g. dentist, mechanic) for three days. This minimizes the risk of a BPPV recurrence.
- Whether a follow-up visit after a successful liberation maneuver is needed, should be decided for each patient individually. Many times, a feedback by phone three days later will do, since the success rate of liberation maneuvers is very high.
- Provocation and liberation maneuvers in frail patients with BPPV cannot be performed at the bedside in the proper way due to stiffness, pain, and angst. These patients are best diagnosed and treated on 2-axis turntables.

References

- Appiani GC, Catania G, Gagliardi M, Cuiuli G (2005) Repositioning maneuver for the treatment of the apogeotropic variant of horizontal canal benign paroxysmal positional vertigo. *Otol Neurotol* 26:257-60.
- Baloh RW, Yue Q, Jacobson KM, Honrubia V (1995) Persistent direction-changing positional nystagmus: another variant of benign positional nystagmus? *Neurology* 45:1297-301.
- Brandt T, Dieterich M, Strupp M (2013) *Vertigo and Dizziness – Common Complaints*. 2nd ed. Springer, London.
- Brandt T, Steddin S, Daroff RB (1994) Therapy of benign paroxysmal positioning vertigo, revisited. *Neurology* 44:796-800.
- Casani AP, Vannucci G, Fattori B, Berrettini S (2002) The treatment of horizontal canal positional vertigo: our experience in 66 cases. *Laryngoscope* 112:172–178.
- Dix MR, Hallpike CS (1952) The pathology, symptomatology and diagnosis of certain common disorders of the vestibular system. *Ann Otol Rhinol Laryngol* 61:987–1016.
- Epley JM (1992) The canalolith repositioning procedure: for treatment of benign paroxysmal positional vertigo. *Otolaryngol Head Neck Surg* 107:399–404.
- Epley JM (2001) Human experience with canalith repositioning maneuvers. *Ann N Y Acad Sci*. 2001:179-91.
- Fife TD (1998) Recognition and management of horizontal canal benign positional vertigo. *Am J Otol* 19:345–51.

- Korres S, Balatsouras DG, Kaberos A, Economou C, Kandiloros D, Ferekidis E (2002) Occurrence of semicircular canal involvement in benign paroxysmal positional vertigo. *Otol Neurotol* 23:926–932.
- Kim JS, Oh SY, Lee SH, Kang JH, Kim DU, Jeong SH, Choi KD, Moon IS, Kim BK, Oh HJ, Kim HJ (2011) Randomized clinical trial for apogeotropic horizontal canal benign paroxysmal positional vertigo. *Neurology* 78:159-66.
- Lempert T (1994) Horizontal benign positional vertigo. *Neurology* 44:2213–2214.
- McClure JA (1985) Horizontal canal BPV. *J Otolaryngol* 14:30–35.
- Obrist D, Nienhaus A, Zamaro E, Kalla R, Mantokoudis G, Strupp M (2016) Determinants for a successful Sémont maneuver: an in vitro study with a semicircular canal model. *Front Neurol* 7:150.
- Pagnini P, Nuti D, Vannucchi P (1989) Benign paroxysmal vertigo of the horizontal canal. *ORL* 51:161–170.
- Semont A, Freyss G, Vitte E (1988) Curing the BPPV with a liberatory maneuver. *Adv Otorhinolaryngol* 42:290–293.
- Seok JI, Lee HM, Yoo JH, Lee DK (2008) Residual dizziness after successful repositioning treatment in patients with benign paroxysmal positional vertigo. *J Clin Neurol* 4:107–110.
- Uneri A (2005) Falling sensation in patients who undergo the Epley maneuver: a retrospective study. *Ear Nose Throat J* 84:82-85.
- Vannucchi P, Giannoni B, Pagnini P (1997) Treatment of horizontal semicircular canal benign paroxysmal positional vertigo. *J Vestib Res* 7:1–6.
- Waespe W (1997) Benign postural vertigo and nystagmus of the horizontal semicircular canal. *Schweiz Med Wochenschr* 127:287–95.