



# Emergency Neurology across all ages with specific emphasis on history and clinical presentation

14th RTC Africa, Dar es Salaam,  
Tanzani

# Acute headache with and without fever

Daniele Martinelli, MD PhD



# Disclosure

---



- I have no financial interests or relationships to disclose in regard to the topic of the presentation.

# International Headache Society



About IHS

Resources/Events

Membership

News

Learning Centre

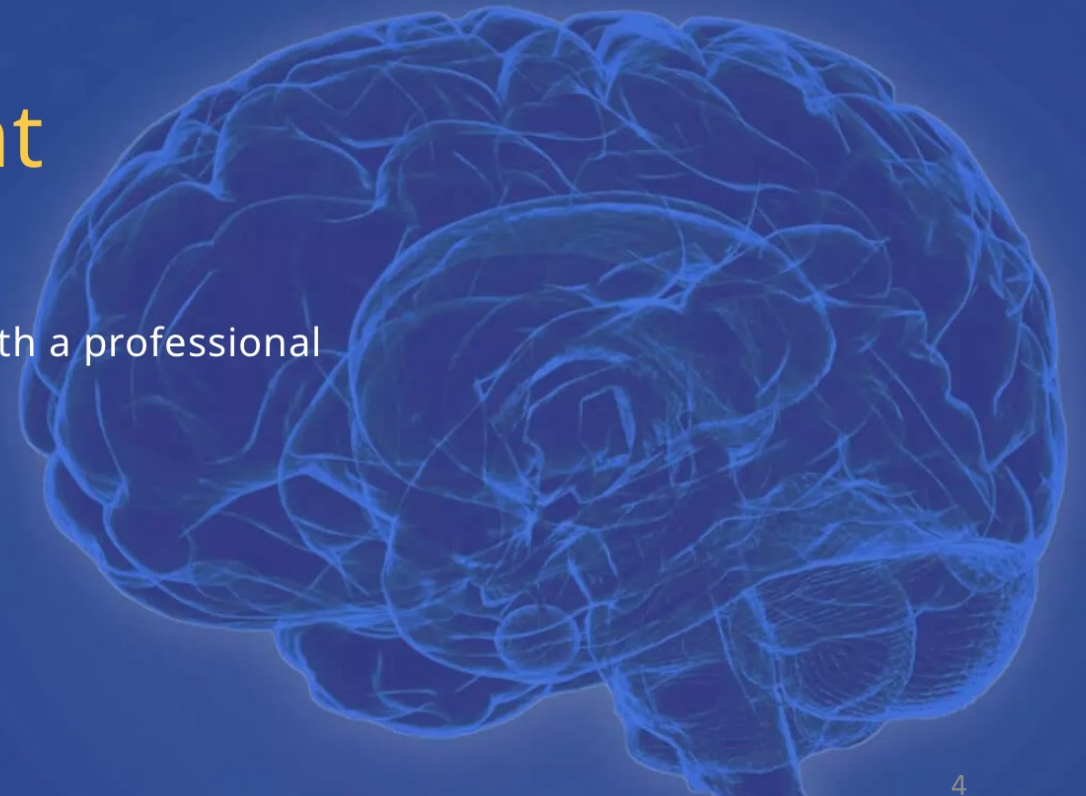Journals ▾

Member Login

## Leading headache science, education and management globally

The world's leading membership organisation for those with a professional commitment to helping people affected by headache

[www.ihs-headache.org/en/](http://www.ihs-headache.org/en/)



# Join the International Headache Society

IHS members are medical and healthcare practitioners (including such practitioners actively involved in scientific research) who are professionally engaged or involved in the study of headache disorders

Membership Application



## Videos & Podcasts

Educational videos on clinical and scientific topics in headache. Podcasts on all aspects of headache with experts from the headache field

Explore

## Learning Institute

The Learning Institute is a series of online courses focusing on different headache disorders

View

---

# Welcome to the Learning Centre

## Core Curriculum

The Core Curriculum defines the minimum knowledge about headache required by neurologists for qualification as a specialist in neurology

View

## Webinars

Quarterly webinars are held as live events on both clinical and scientific headache topics presented by worldwide headache experts. Past recorded webinars are also available

Explore



[Home](#)

[How to use the classification](#)

[Classification](#)

## Part I: The primary headaches

### 1. Migraine

[2. Tension-type headache \(TTH\)](#)

[3. Trigeminal autonomic cephalalgias \(TACs\)](#)

[4. Other primary headache disorders](#)

## Part II: The secondary headaches

[5. Headache attributed to trauma or injury to the head and/or neck](#)

[6. Headache attributed to cranial or cervical](#)



En

## 1. Migraine

### 1.1 Migraine without aura

### 1.2 Migraine with aura

#### 1.2.1 Migraine with typical aura

1.2.1.1 Typical aura with headache

1.2.1.2 Typical aura without headache

#### 1.2.2 Migraine with brainstem aura

#### 1.2.3 Hemiplegic migraine

##### 1.2.3.1 Familial hemiplegic migraine (FHM)

1.2.3.1.1 Familial hemiplegic migraine type 1 (FHM1)

1.2.3.1.2 Familial hemiplegic migraine type 2 (FHM2)

1.2.3.1.3 Familial hemiplegic migraine type 3 (FHM3)

1.2.3.1.4 Familial hemiplegic migraine, other loci

##### 1.2.3.2 Sporadic hemiplegic migraine (SHM)

#### 1.2.4 Retinal migraine

### 1.3 Chronic migraine

### 1.4 Complications of migraine

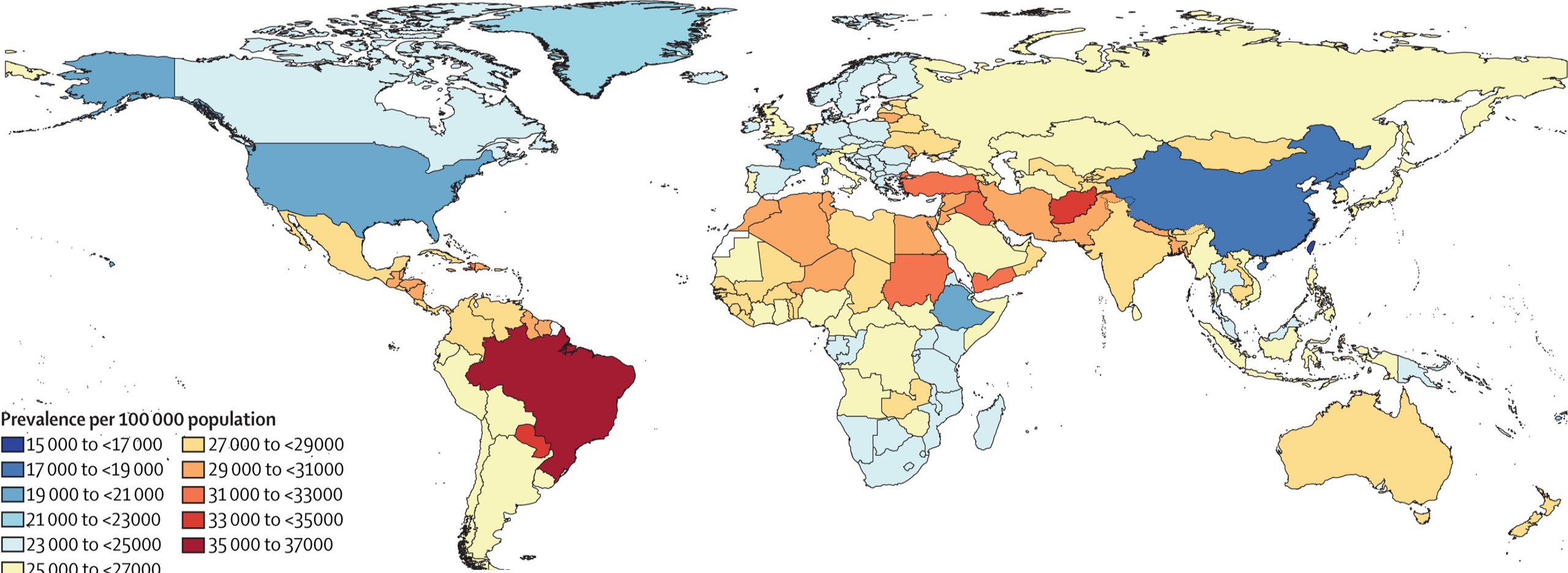
1.4.1 Status migrainosus

1.4.2 Persistent aura without infarction

1.4.3 Migrainous infarction

1.4.4 Migraine aura-triggered seizure





# Migraine prevalence

- Prevalence: 1,04 billion (95% uncertainty interval [UI] 1.00–1.09)
- Years of life lived with disability (YLDs) in 2016: 45.1 million (95% UI 29.0–62.8)
- Global age-standardised prevalence was 14.4% (13.8–15.0) overall:
  - 18.9% (18.1–19.7) for women,
  - 9.8% (9.4–10.2) for men
- Migraine was the second cause of disability after low back pain

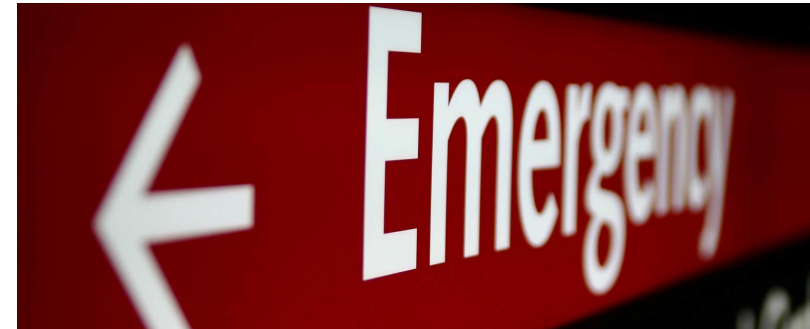



# Headache: a reason to be admitted

Patients come to the Emergency Department for 3 main reasons:

- 1) Headache associated with other signs and symptoms (eg fever)
- 2) The first or worst attack syndrome
- 3) The last straw syndrome



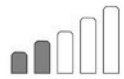

**Table 1** Common presenting complaints and diagnoses at a short-lived adult neurology clinic at Queen Elizabeth Central Hospital, Malawi

Top 5 presenting complaints	Frequency (%)
Headache	27.5
Seizures	20.6
Weakness	14.7
Tremor	6.8
Dizziness/Ataxia	3.9

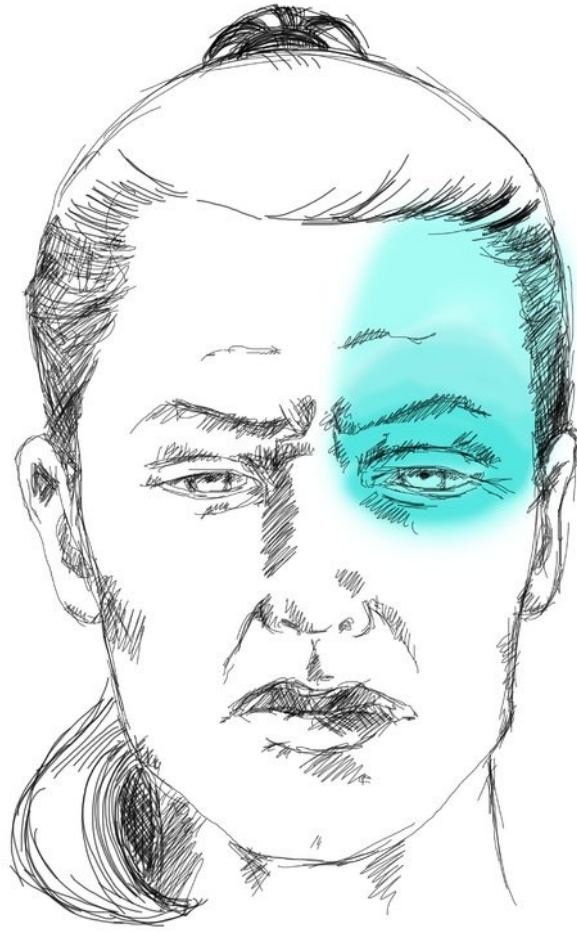Top 5 diagnoses	Frequency (%)
Headache disorders (migraine and tension-type headache representing up to 70%)	24.5
Epileptic disorders	20.0
Polyneuropathy	7.0
Stroke	4.0
Traumatic and degenerative disorders of the spine	4.0

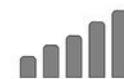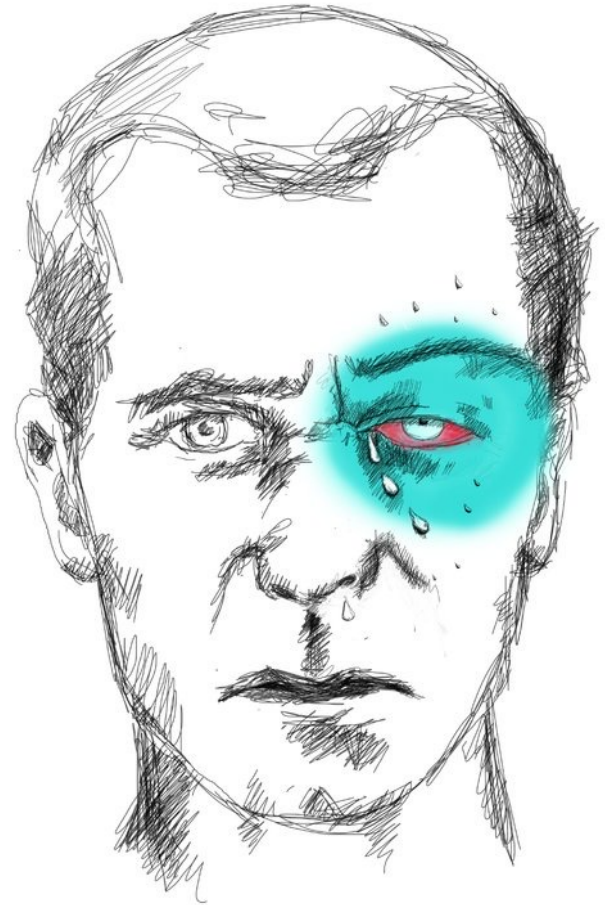
- In Italy, overall headache represents 1,7-4,5% of the reasons of ED presentation
- 12% of the neurological evaluations in ED



**Tension headache**



**Migraine**



**Cluster headache**

Secondary headache prevalence:

- Emergency: 2% to 7%
- community-based: 2% to 23%



# Diagnostic tools

Appropriate history  
Appropriate neurological examination  
Vital signs

Method	Routine evaluation	Level of recommendation [4]
EEG	Recommended for basilar/hemiplegic migraine and epilepsy-related migraine	IIB
Evoked potentials	Not recommended	IIB
Reflex responses	Not recommended	IV/IIIC
Autonomic tests	Not recommended	IIIC
Clinical tenderness test and surface EMG	Not recommended for diagnosis; manual palpation useful for classification	IIB
Neuroimaging	MRI recommended in patients with trigeminal autonomic cephalalgias, atypical headache, CT scan recommended in patients with focal neurological signs	
CSF analysis	is recommended in emergency suspect of meningitis	

# NEUROLOGICAL ANAMNESIS

HOW TO TAKE THE NEUROLOGICAL HISTORY



# Important Historical Points in the Headache Patient

---

- Location of the pain (e.g., hemicranial, holocranial, occipitounuchal, band-like)
- Pain intensity
- Pain quality (e.g., steady, throbbing, stabbing)
- Severity
- Timing, duration, and frequency
- Average daily caffeine intake
- Average daily analgesic intake (including over-the-counter medications)
- Precipitating factors (e.g., alcohol, sleep deprivation, oversleeping, foods, bright light)
- Relieving factors (e.g., rest/quiet, dark room, activity, medications)
- Response to treatment
- Neurologic accompaniments (e.g., numbness, paresthesias, weakness, speech disturbance)
- Visual accompaniments (e.g., scintillating scotoma, transient blindness)
- Gastrointestinal accompaniments (e.g., nausea, vomiting, anorexia)
- Associated symptoms (e.g., photophobia, phonophobia/sonophobia, tearing, nasal stuffiness)
- Any history of head trauma



# Other Important Points

---


- **Past Medical History:** Ask about whether the patient has been diagnosed with any medical condition. If so, ask about the management of these conditions, and any complications.
- **HIV status**
- **Medication History:** Ask about what medication the patient takes regularly, what they take them for, and what side effects they have had.
- **Family history:** Ask whether anyone in the family has had any neurologic conditions in the past. Attempt to determine whether any conditions have a clear pattern of transmission - autosomal dominant, autosomal recessive or X-linked.
- **Social History:** It is important to understand any patient's social situation when taking their history. This includes key aspects such as their occupation (or previous occupation, if retired), living situation, mobility, ability to perform activities of the daily living, diet and exercise
- **Substance History**
  - Take a detailed [smoking history](#): identify how many years the patient has smoked for, how many they smoked per day, and how long since they quit (if applicable).
  - Ask about [alcohol intake](#): how many drinks the patient has per week, what type of drinks, and whether they have considered cutting down their intake if heavy.
  - Finally, ask about [recreational drug use](#), and particularly intravenous drug use.

## SPECIFIC FEATURES OF THE EXAMINATION IN HEADACHE PATIENTS

- DRAW VISUAL DEFECTS
- EVALUATE THE OPTIC DISK
- TEST FOR TEMPOROMANDIBULAR JOINT DISORDER
- TEST FOR NEURALGIC PAIN
- TEST FOR PERICRANIAL MUSCLES TENDERNESS
- EXCLUDE TEMPORAL ARTERITIS
- EXCLUDE MENINGEAL SIGNS
- EXCLUDE FOCAL NEUROLOGICAL SIGNS




# Green Flags



1. The current headache has already been present during childhood.
2. The headache occurs in temporal relationship with the menstrual cycle.
3. The patient has headache-free days.
4. Close family members have the same headache phenotype.
5. Headache occurred or stopped more than one week ago.






# Red flags: history




Characteristic clinical feature	Suspected etiology	Supportive associated features	Common alternative underlying causes
Anticoagulant medication use	<b>Subdural hematoma</b>	<ul style="list-style-type: none"><li>•Neurologic deficits (eg, hemiparesis)</li></ul>	<ul style="list-style-type: none"><li>•Other forms of intracranial hemorrhage (eg, ICH, EDH, SAH)</li></ul>
Analgesic medication use	<b>Medication overuse headache</b>		<ul style="list-style-type: none"><li>•Other primary and secondary headache syndromes*</li></ul>
Pregnancy	<b>Preeclampsia</b>	<ul style="list-style-type: none"><li>•Elevated blood pressure</li><li>•Blurred vision</li><li>•Epigastric/retrosternal pain</li></ul>	<ul style="list-style-type: none"><li>•RPLS</li><li>•CVT</li></ul>
Onset at age >50 years	<b>Tumor</b>	<ul style="list-style-type: none"><li>•Neurologic deficits (eg, hemiparesis, vision loss)</li></ul>	<ul style="list-style-type: none"><li>•GCA</li><li>•Cerebral abscess</li></ul>
Immunosuppressive state	<b>Infectious meningitis</b>		<ul style="list-style-type: none"><li>•RPLS</li></ul>
Carbon monoxide exposure	<b>Carbon monoxide toxicity</b>	<ul style="list-style-type: none"><li>•Dizziness</li><li>•Nausea</li></ul>	<ul style="list-style-type: none"><li>•Other primary and secondary headache syndromes</li></ul>



# Red flags: symptoms



Characteristic clinical feature	Suspected etiology	Supportive associated features	Common alternative underlying causes
Sudden-onset severe headache	<b>Aneurysmal rupture - subarachnoid hemorrhage (SAH)</b>	<ul style="list-style-type: none"><li>•Meningismus</li><li>•Progressive neurologic deterioration</li></ul>	<ul style="list-style-type: none"><li>•RCVS</li><li>•Primary headache associated with sexual activity</li><li>•ICH</li></ul>
Visual disturbances	<b>Glaucoma</b>	<ul style="list-style-type: none"><li>•Halos appear around light</li><li>•Blurred vision</li></ul>	<ul style="list-style-type: none"><li>•Migraine</li><li>•IIH (Pseudotumor cerebri)</li><li>•GCA</li></ul>
Orthostatic headache	<b>Spontaneous intracranial hypotension</b>	<ul style="list-style-type: none"><li>•Worsens with Valsalva maneuvers</li><li>•Tinnitus/hearing loss</li></ul>	<ul style="list-style-type: none"><li>•Cervicogenic headache</li><li>•Postural orthostatic tachycardia syndrome</li></ul>



# Red flags: signs



Characteristic clinical feature	Suspected etiology	Supportive associated features	Common alternative underlying causes
Fever and meningismus	<b>Infectious meningitis</b>		<ul style="list-style-type: none"><li>•SAH</li><li>•GCA</li></ul>
Elevate Blood Pressure	<b>reversible cerebral vasoconstriction syndrome (RCVS)</b>	<ul style="list-style-type: none"><li>•Confusion</li><li>•Neurologic deficits (eg, hemiparesis, vision loss)</li></ul>	<ul style="list-style-type: none"><li>•Intra Cranial Haemorrhage</li><li>•Ischemic stroke</li><li>•Preeclampsia</li></ul>
Papilledema	<b>IIH (Pseudotumor cerebri)</b>	<ul style="list-style-type: none"><li>•Visual field defects</li><li>•Nausea/vomiting</li></ul>	<ul style="list-style-type: none"><li>•Tumor</li><li>•Optic neuritis</li><li>•Nonarteritic ischemic optic neuropathy</li></ul>
Horner syndrome	<b>Carotid artery dissection</b>	<ul style="list-style-type: none"><li>•Ischemic stroke symptoms</li><li>•Lower cranial nerve deficits</li></ul>	<ul style="list-style-type: none"><li>•Cluster headache</li><li>•Migraine</li></ul>

# Findings indicative of secondary headache



FINDING	RULE OUT
Vital Signs	
Elevated temperature	Infectious causes, GCA
Elevated blood pressure	PRES, CVD
Tachycardia	Orthostatic hypotension, POTS
Bradycardia	Hypothyroidism
Body mass index > 25	Idiopathic intracranial hypotension
General	
Wasted appearance	HIV, Malignancy GCA
Joint hypermobility Skin laxity	Intracranial hypotension Intracranial aneurysm Cervical artery dissection
Hair loss, Dry skin, Edema, Hoarse voice	Hypothyroidism
Diaphoresis, Rhinorrhea, Mydriasis, Restlessness, Yawning, Tremor	Opioid withdrawal

Cardiac	
Temporal artery tenderness/ induration Diminished/asymmetric pulse Aortic regurgitation	GCA
Neurologic	
Papilledema	Intracranial hypertension
Horner's sign	Carotid artery dissection
Trigeminal sensation loss	Trigeminal neuropathy
Abducens paresis	Intracranial hypertension Other focal lesion
Oculomotor paresis and/or mydriasis	Intracranial aneurysm, ION Other focal lesion
Head and Neck	
Trochlear tenderness aggra- vated by vertical duction	Trochlear headache
Tympanic vesicles	Herpes zoster
Hard papule near frenulum or adjacent to 2nd upper molar	Sialolithiasis
Restricted neck rotation	C2/3 facet arthropathy
Pericranial and/or occipital nerve tenderness	Trigeminal branch or occipital neuralgia
Limited TMJ range of motion	TMJ syndrome

CNS, central nervous system; CVD, cerebrovascular disease; GCA, giant cell arteritis; ION, ischemic ocular neuropathy; POTS, postural orthostatic tachycardia syndrome; PRES, posterior reversible encephalopathy syndrome; TMJ, temporomandibular joint.



# Arterial Hypertensive crisis

Headache, often bilateral and pulsating, caused by arterial hypertension, usually during an acute rise in systolic (to  $\geq 180$  mm Hg) and/or diastolic (to  $\geq 120$  mm Hg) blood pressure.


It remits after normalising blood pressure and worsens when arterial hypertension is uncontrolled.

Associated symptoms :

- nasal bleeding
- subconjunctival haemorrhage
- Facial flushing
- Dizziness

BLOOD PRESSURE CATEGORY	SYSTOLIC mm Hg (upper number)		DIASTOLIC mm Hg (lower number)
<b>NORMAL</b>	<b>LESS THAN 120</b>	<b>and</b>	<b>LESS THAN 80</b>
<b>ELEVATED</b>	<b>120 – 129</b>	<b>and</b>	<b>LESS THAN 80</b>
<b>HIGH BLOOD PRESSURE (HYPERTENSION) STAGE 1</b>	<b>130 – 139</b>	<b>or</b>	<b>80 – 89</b>
<b>HIGH BLOOD PRESSURE (HYPERTENSION) STAGE 2</b>	<b>140 OR HIGHER</b>	<b>or</b>	<b>90 OR HIGHER</b>
<b>HYPERTENSIVE CRISIS (consult your doctor immediately)</b>	<b>HIGHER THAN 180</b>	<b>and/or</b>	<b>HIGHER THAN 120</b>

# Red Flags



**Table 1** SNNOOP10 list of red and orange flags

	Sign or symptom	Related secondary headaches (most relevant ICHD-3b categories)	Flag color
1	Systemic symptoms including fever	Headache attributed to infection or nonvascular intracranial disorders, carcinoid or pheochromocytoma	Red (orange for isolated fever)
2	Neoplasm in history	Neoplasms of the brain; metastasis	Red
3	Neurologic deficit or dysfunction (including decreased consciousness)	Headaches attributed to vascular, nonvascular intracranial disorders; brain abscess and other infections	Red
4	Onset of headache is sudden or abrupt	Subarachnoid hemorrhage and other headaches attributed to cranial or cervical vascular disorders	Red
5	Older age (after 50 years)	Giant cell arteritis and other headache attributed to cranial or cervical vascular disorders; neoplasms and other nonvascular intracranial disorders	Red
6	Pattern change or recent onset of headache	Neoplasms, headaches attributed to vascular, nonvascular intracranial disorders	Red
7	Positional headache	Intracranial hypertension or hypotension	Red
8	Precipitated by sneezing, coughing, or exercise	Posterior fossa malformations; Chiari malformation	Red
9	Papilledema	Neoplasms and other nonvascular intracranial disorders; intracranial hypertension	Red
10	Progressive headache and atypical presentations	Neoplasms and other nonvascular intracranial disorders	Red
11	Pregnancy or puerperium	Headaches attributed to cranial or cervical vascular disorders; postdural puncture headache; hypertension-related disorders (e.g., preeclampsia); cerebral sinus thrombosis; hypothyroidism; anemia; diabetes	Red
12	Painful eye with autonomic features	Pathology in posterior fossa, pituitary region, or cavernous sinus; Tolosa-Hunt syndrome; ophthalmic causes	Red
13	Posttraumatic onset of headache	Acute and chronic posttraumatic headache; subdural hematoma and other headache attributed to vascular disorders	Red
14	Pathology of the immune system such as HIV	Opportunistic infections	Red
15	Painkiller overuse or new drug at onset of headache	Medication overuse headache; drug incompatibility	Red



# Thunderclap headache

- A TCH is a very severe headache of abrupt onset that reaches its **maximum intensity within one minute or less of onset**.
- The key feature that differentiates TCH from other headaches is the **rapidity** with which it develops; extreme severity alone is insufficient.
- Presented in **isolation** or accompanied by **additional symptoms and signs** that reflect the underlying cause: meningismus, fever, tinnitus, orthostatic worsening of headache, altered mental state, seizure, motor or sensory deficits, or cranial nerve palsies



**MEDICAL EMERGENCY**



# Ottawa Subarachnoid Hemorrhage (SAH) Rule for Headache Evaluation

Age $\geq 40$	No 0	Yes +1
Neck pain or stiffness	No 0	Yes +1
Witnessed loss of consciousness	No 0	Yes +1
Onset during exertion	No 0	Yes +1
Thunderclap headache (instantly peaking pain)	No 0	Yes +1
Limited neck flexion on examination	No 0	Yes +1

## INSTRUCTIONS

This rule has very specific inclusion and exclusion criteria that must be followed closely for appropriate application:

**Only apply in:** Alert patients  $\geq 15$  years old, new severe atraumatic headache, maximum intensity within 1 hour.

**Do not use in:** Patients with new neurologic deficits, prior aneurysm, prior SAH, known brain tumors, or chronic recurrent headaches ( $\geq 3$  headaches of the same character and intensity for  $>6$  months).

## ADVICE

- Consider SAH workup in patients with ANY positive criteria, but as with other rule-out decision aids, just because a patient fails the rule does not require that all patients are then evaluated for SAH, given its very low specificity.
- May consider avoiding further SAH-specific workup in patients with all negative criteria.





# Thunderclap headache

---

Other clinical presentations may suggest specific causes of TCH:

- Recurrent TCH over days to weeks suggest reversible cerebral vasoconstriction syndrome (RCVS)
- TCH associated with orthostatic headaches suggests spontaneous intracranial hypotension
- Postpartum setting suggests RCVS or cerebral venous thrombosis
- Recent minor trauma suggests cervical artery dissection or spontaneous intracranial hypotension
- Horner syndrome or pulsatile tinnitus suggests dissection of the ipsilateral internal carotid artery
- Papilledema and visual symptoms suggest intracranial hypertension related to cerebral venous thrombosis
- Fever or meningismus suggests meningitis
- Facial pain, ear, nose, and throat symptoms suggest complicated sinusitis



# Headache + Fever

## Headache + fever alone: aspecific

- non-specific
- peripheral infection more likely than CNS infection

(malaria, enteric fever, covid-19, flu etc.)

Headache+ fever + **Neurological signs** =  
**increased likelihood**

seizures

nuchal rigidity or any other meningeal signs

unilateral weakness

### Intracranial infection

Meningitis

Bacterial

Fungal

Viral

Lymphocytic

Encephalitis

Brain abscess

Subdural empyema

### Systemic infection

Bacterial infection

Viral infection

HIV/AIDS

Other systemic infection

### Other causes

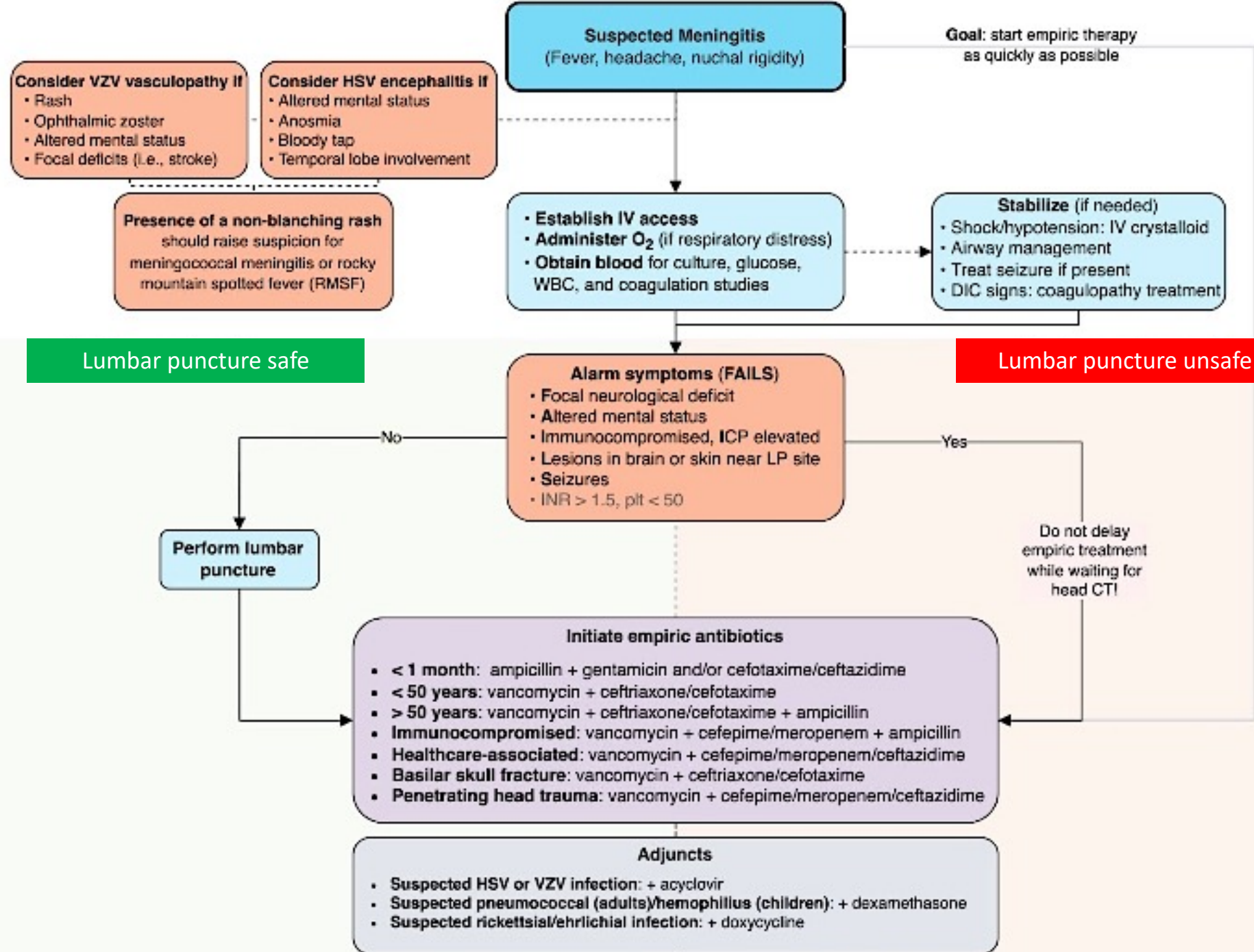
Familial hemiplegic migraine

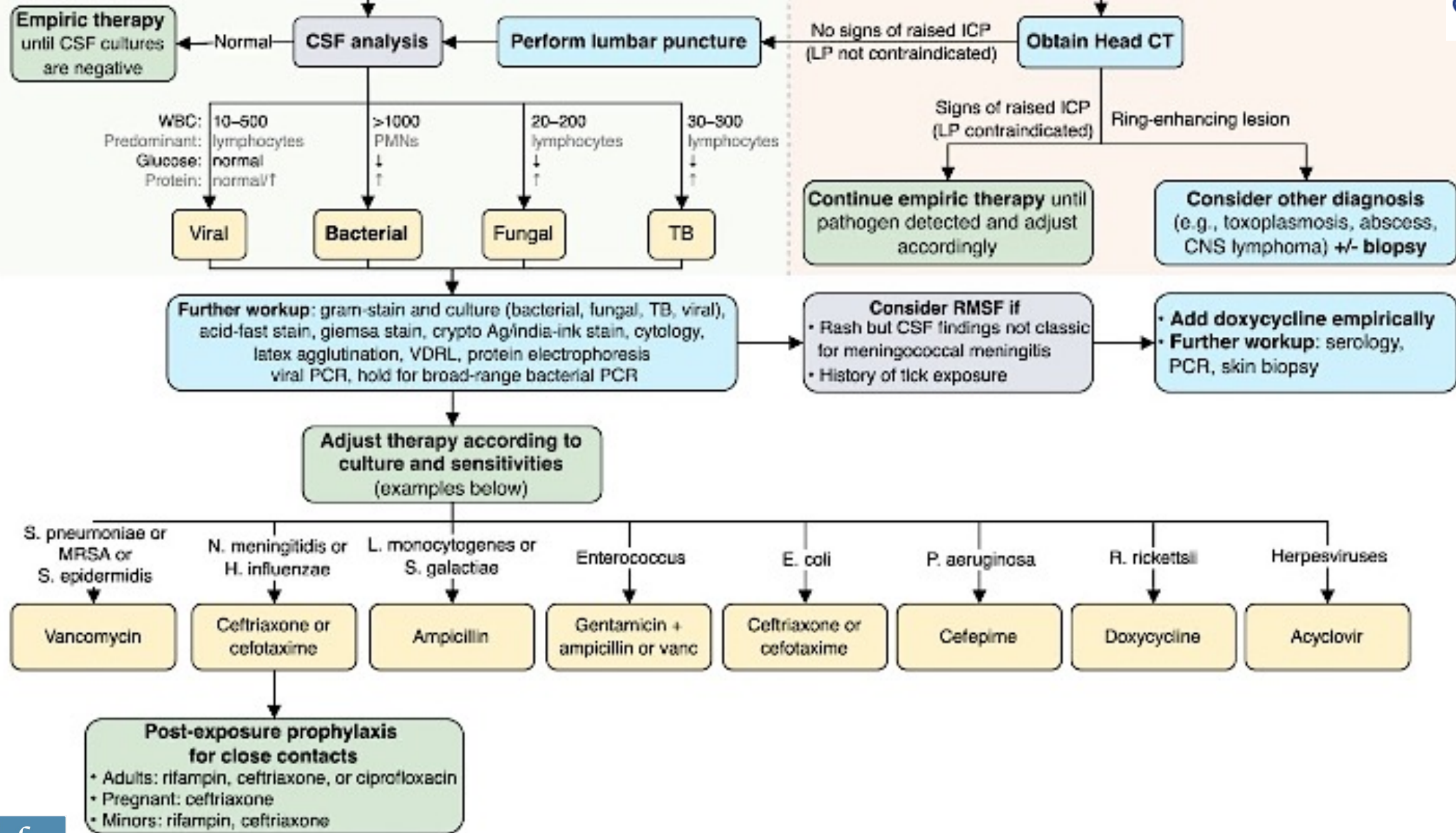
Pituitary apoplexy

Rhinosinusitis

Subarachnoid hemorrhage

Malignancy of central nervous system







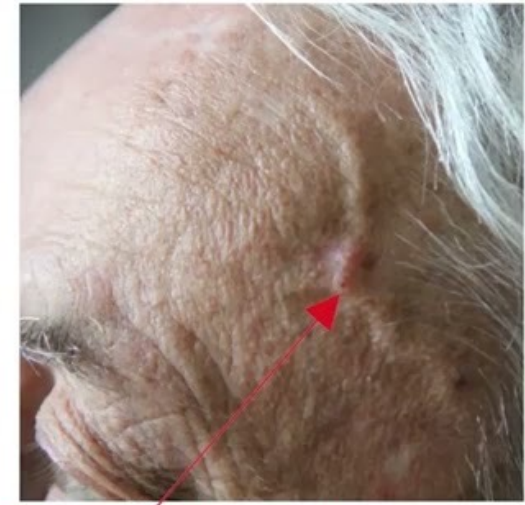# Headache + fever: CNS involmment of a sistemic disease

## Temporal Arteritis (Giant cell arteritis)

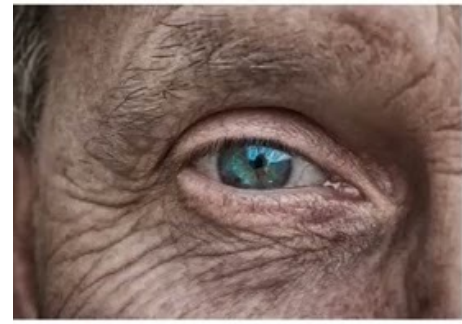Older Women (>50)  
Throbbing headache  
Visual Problems  
(Blindness)

Inflammation of  
arteries

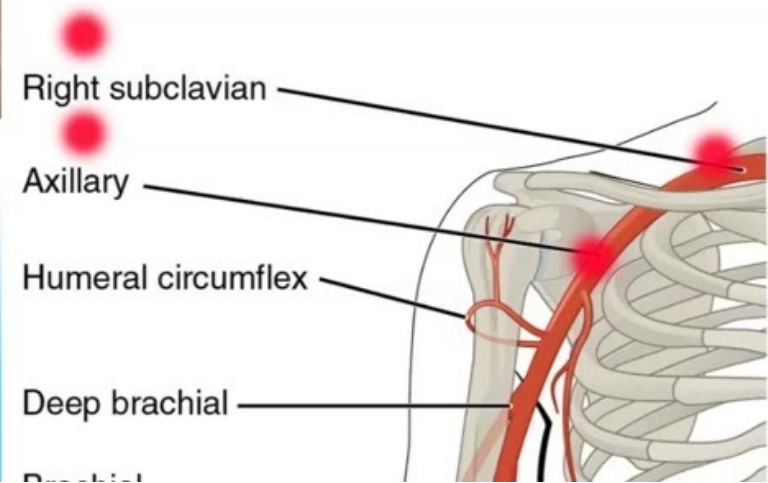
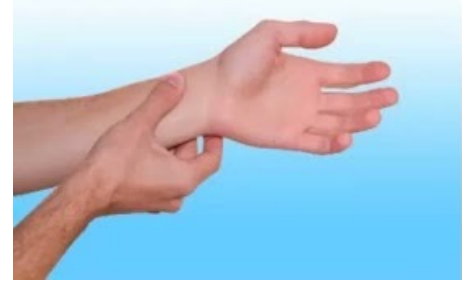Facial pain



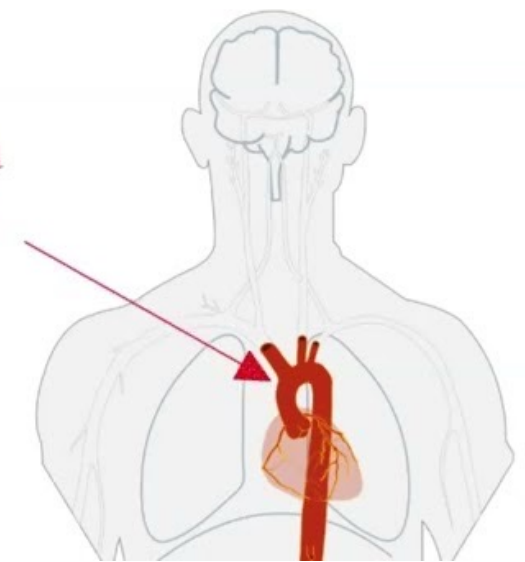
Tender, Firm nodules



Weak Pulse



Aortic arch  
inflammation



Common  
headache  
emergencies  
in pregnant  
patients

Description	Possible diagnosis
Unilateral, throbbing, photophobia, phonophobia, osmophobia, nausea/vomiting, improved with sleep	Migraine <sup>a</sup>
Nonspecific and unremitting seizures, focal neurological symptoms, signs of raised ICP	Cerebral venous sinus thrombosis
Headache refractory to analgesia Hypertension, proteinuria	Preeclampsia/eclampsia (headache can be sentinel feature to eclampsia)
Blurred vision, scotoma, flashing lights	PRES from hypertension
Thunderclap, fluctuating neurological deficits, seizures	Reversible cerebral vasoconstriction syndrome (postpartum vasculopathy)
Thunderclap, orbitofrontal or diffuse Nausea, vomiting, hypotension, vision loss (bitemporal hemianopia), altered consciousness	Pituitary apoplexy
Thunderclap, often unilateral Nausea, vomiting, neck stiffness, altered consciousness	Subarachnoid hemorrhage
Diffuse, neck pain, meningismus, possibly thunderclap Cranial neuropathies, fever	Meningitis/meningoencephalitis
Diffuse, worse with coughing or Valsalva Papilledema, sixth nerve palsy	Space-occupying lesion or other causes of increased intracranial pressure (including idiopathic intracranial hypertension)
Nonspecific quality, moderate intensity Focal neurologic symptoms	Acute ischemic stroke

Headache feature	Tension-type headache	Migraine (with or without aura)	Cluster headache
Pain location (can be in the head, face or neck)	Bilateral	Unilateral or bilateral	Unilateral (around the eye, above the eye and along the side of the head/face)
Pain quality	Pressing/tightening (non-pulsating)	Pulsating (throbbing or banging in young people aged 12 to 17 years)	Variable (can be sharp, boring, burning, throbbing or tightening)
Pain intensity	Mild or moderate	Moderate or severe	Severe or very severe
Effect on activities	Not aggravated by routine activities of daily living	Aggravated by, or causes avoidance of, routine activities of daily living	Restlessness or agitation
Other symptoms	None	<p>Unusual sensitivity to light and/or sound or nausea and/or vomiting</p> <p>Symptoms of aura can occur with or without headache and:</p> <ul style="list-style-type: none"> <li>are fully reversible</li> <li>develop over at least 5 minutes</li> <li>last 5 to 60 minutes</li> </ul> <p>Typical aura symptoms include visual symptoms such as flickering lights, spots or lines and/or partial loss of vision; sensory symptoms such as numbness and/or pins and needles; and/or speech disturbance</p>	<p>On the same side as the headache:</p> <ul style="list-style-type: none"> <li>red and/or watery eye</li> <li>nasal congestion and/or runny nose</li> <li>swollen eyelid</li> <li>forehead and facial sweating</li> <li>constricted pupil and/or drooping eyelid</li> </ul>
Duration of headache	30 minutes to continuous	<p>4 to 72 hours in adults</p> <p>1 to 72 hours in young people aged 12 to 17 years</p>	15 to 180 minutes



# Migraine Emergency rescue therapy

- Acute migraine is a common presentation in the emergency department (ED).
- **Nonsteroidal anti-inflammatory drugs, antiemetic medications, diphenhydramine, dexamethasone, and intravenous fluids** all have shown benefit for treating acute migraine in the ED.
- Opioids are, at best, a third-line treatment for acute migraine in the ED and their use is therefore discouraged.
- Their effect is greater when they are all administered up front as opposed to being delivered in a stepwise pattern throughout the ED stay.

Treatment	Canadian Headache Society		
	Recommendation	Strength of Recommendation	
Ketorolac	Use	Strong	
Dopamine Antagonists	Metoclopramide	Use	Strong
	Prochlorperazine	Use	Strong
Triptans	Sumatriptan	Use	Strong

The following are reasonable options, with evidence of efficacy from randomized trials:

[Sumatriptan](#) 6 mg subcutaneous injection

Antiemetics-dopamine receptor:

- [Prochlorperazine](#) 10 mg intravenous (IV) or intramuscular (IM)
- [Metoclopramide](#) 10 mg IV
- [Chlorpromazine](#) 0.1 mg/kg (or 12.5 mg) single dose as a slow IV infusion (maximum rate 1 mg/minute); maximum cumulative dose 25 mg

[Ketorolac](#) 30 mg IV or 60 mg IM (15 mg IV or 30 mg IM for patients  $\geq 65$  years,  $< 50$  kg, or renal impairment)

[Dihydroergotamine](#) (1 mg IV) combined with [metoclopramide](#) (10 mg IV)





# Desametasone

## Randomized Trial Comparing Low- vs High-Dose IV Dexamethasone for Patients With Moderate to Severe Migraine

Benjamin W. Friedman, MD, Clemencia Solorzano, PharmD, Benjamin D. Kessler, MD, Kristina Martorello, FNP, Carlo L. Lutz, MD, MS, Carmen Feliciano, RN, Nicole Adler, FNP, Hillary Moss, MD, Darnell Cain, MD, and Eddie Irizarry, MD

**Correspondence**  
Dr. Friedman  
bwfriedmanmd@gmail.com

*Neurology*® 2023;101:e1448-e1454. doi:10.1212/WNL.0000000000207648

- Thirty-five of 102 (34%) participants in the metoclopramide +4 mg arm achieved **sustained headache relief** as did 42/102 (41%) participants in the metoclopramide +16 mg arm (absolute difference 7%, 95% CI -6% to 20%).
- **Headache relief within 2 hours** occurred in 77/104 (74%) low-dose and 82/105 (78%) high-dose participants (absolute difference 4%, 95% CI -8% to 16%).

### Classification of Evidence

This study provides Class I evidence that 16 mg of IV dexamethasone is unlikely to provide greater rates of sustained headache relief than 4 mg of IV dexamethasone among patients in the ED with migraine treated concurrently with IV metoclopramide.



# Abortive agents in cluster headache: triptans

---

## Sumatriptan 6mg s.c.



The most effective self-administered medication for the symptomatic relief of CH (Dodick et al., 2000)

Fast (15 min) response: CCH<ECH (8%)

Safe: no tachyphylaxis or rebound

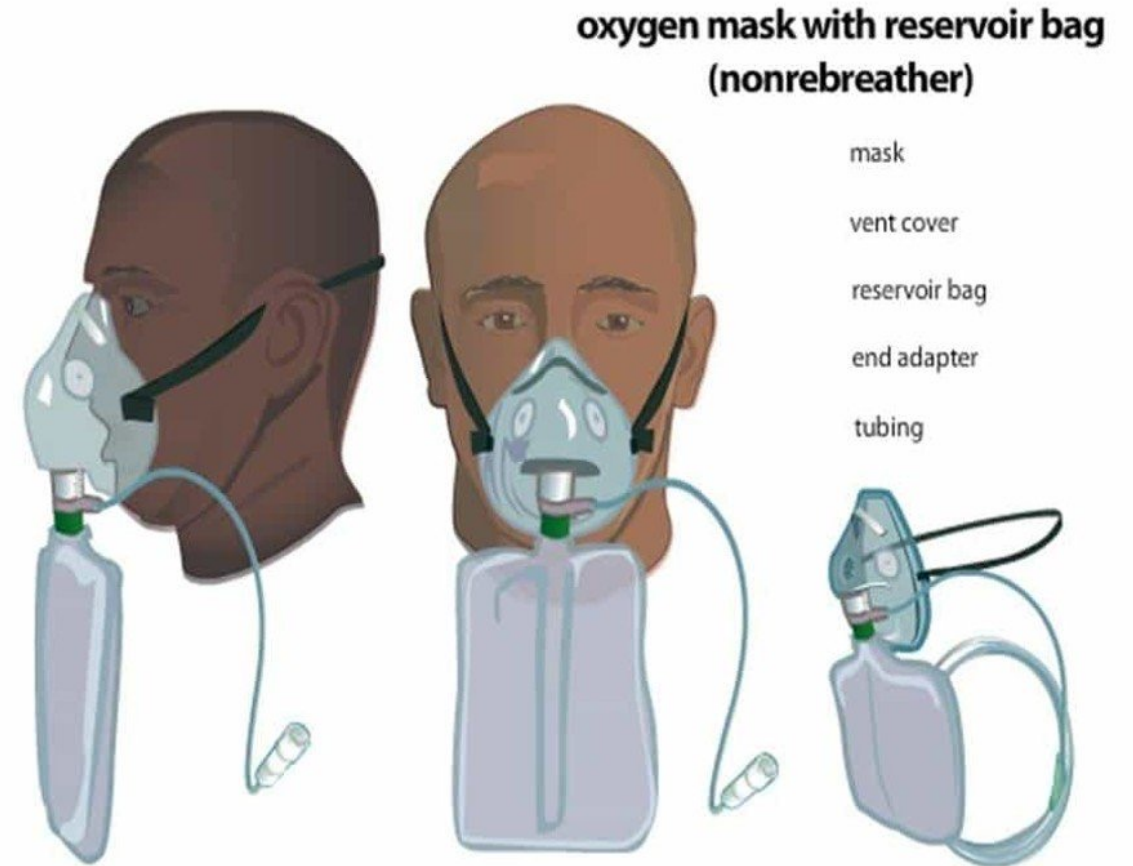
- **Sumatriptan intranasal** → less effective than s.c. (Hardebo, 1998)
- **Zolmitriptan** → significantly better than placebo (Bahra et al., 2000)



# Abortive agents in cluster headache: oxygen

## Normobaric oxygen administration

- 15l/min with reservoir bag
- The inhalation should continue for 15 minutes to prevent the attack from returning
- relief of pain in 62-75% of patients, withing 5 minutes
- low preference, no adverse events, shift of the attacks (25%). (Kudrow, 1981; Fogan, 1985)





# Abortive agents in cluster headache

---

- **Lidocaine** — Intranasal [lidocaine](#) (1 mL) is administered **ipsilateral** to the pain in a 4 to 10 per cent solution. The head position should be in extension by 45 degrees and rotated toward the symptomatic side by 30 to 40 degrees.
- **Ergots** — Ergotamine is available as a 2 mg sublingual tablet. The initial dose is 2 mg and may be repeated every 30 minutes with a maximum dose of 6 mg daily and 10 mg a week.
  - Ergots are contraindicated during pregnancy because of the potential to induce hypertonic uterine contractions and vasospasm/vasoconstriction, which could cause adverse fetal effects.
- **Octreotide** — [Octreotide](#) (100 mg) may be effective in the treatment of acute cluster headaches.
  - Although there has been no direct comparison of [octreotide](#) with triptans, the results of this study suggest that octreotide is inferior to both subcutaneous [sumatriptan](#) 6 mg [19] and intranasal sumatriptan 20 mg [22] in terms of response rate and time to initial relief.
- **Corticosteroids** are effective to bridge the time interval in new bouts of episodic cluster headache or chronic cluster headache until preventive drug therapy becomes effective. Corticosteroids can be used orally with dose tapering, as an intravenous injection, and in the form of ipsilateral injections into the area of the greater occipital nerve.



# Nerve blockage

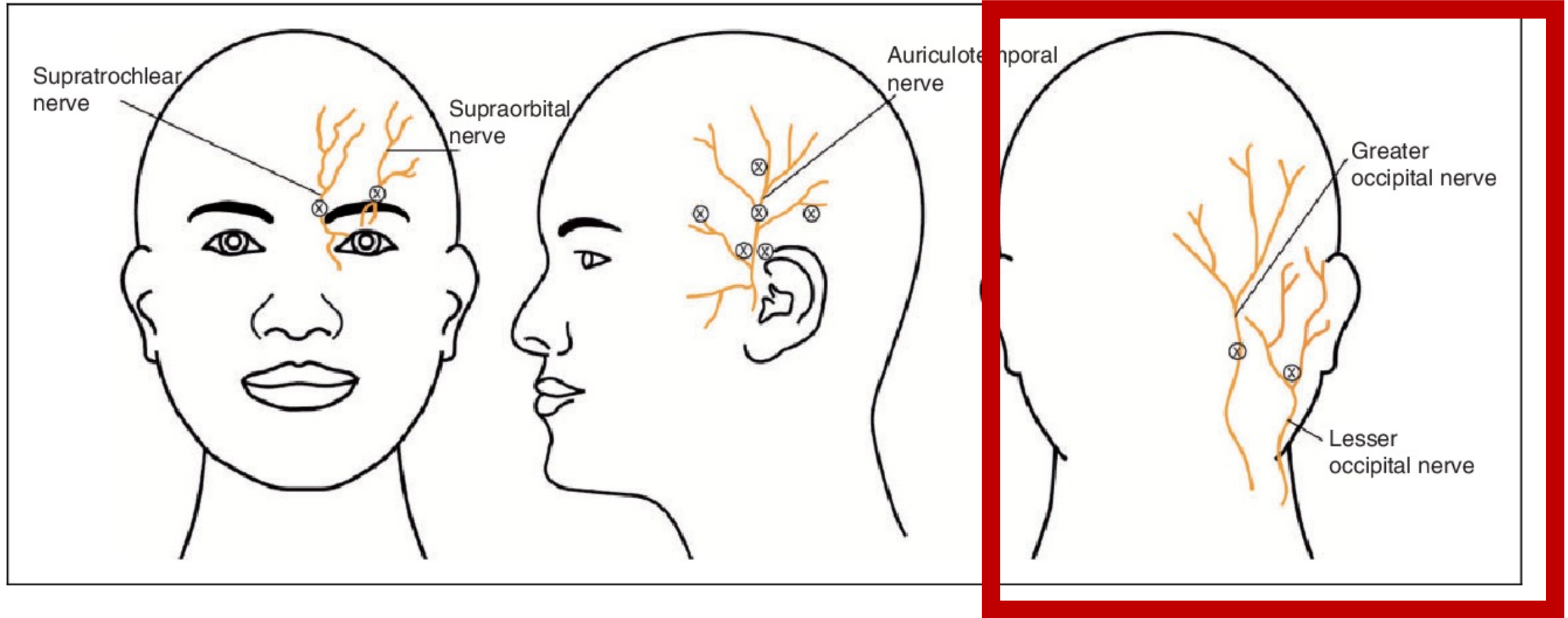
- Peripheral nerve blocks have a role in acute and transitional treatment of acute migraine, chronic migraine, cluster headache and painful cranial neuralgias.
- Patient position and anatomical landmarks are key for their successful delivery.
- Corticosteroids are frequently used for greater occipital nerve blocks but may also be used for lesser occipital nerve blocks.
- Supraorbital, supratrochlear and auriculotemporal nerve blocks involve a combination of lidocaine and/or bupivacaine.
- Uncommon but important adverse effects include transient dizziness, light-headedness, transient headache exacerbation, and rarely localised lipoatrophy and alopecia with corticosteroids.

**Table 1** Evidence base for the efficacy of peripheral nerve block in treating different headache disorders

Headache disorder	Type of nerve block studied	Evidence level*
Acute migraine	GON	2B <sup>8</sup>
Chronic migraine	GON	2A <sup>9 10</sup>
Cluster headache	GON, suboccipital	1B <sup>11 12</sup>
Occipital neuralgia	GON	2B <sup>13</sup>
Chronic daily headache	GON	2B <sup>14</sup>
Other trigeminal autonomic cephalalgias		
SUNCT/SUNA	Supraorbital, supratrochlear	4 <sup>5</sup>
Paroxysmal hemicrania/hemicrania continua	Supraorbital, supratrochlear	4 <sup>15</sup>
Other painful cranial neuralgias	Supraorbital, auriculotemporal	4 <sup>16 17</sup>



# Nerve blockage



Methylprednisolone 40 mg/ml (2 ml)  
Lidocaine 2% (2ml)



# Take home messages: diagnostic keys

---



## History



Obtain a thorough history, examination and identify headache red flags.



If there is a high index of suspicion for a secondary cause of headache, pursue basic serologic testing to exclude systemic conditions



Consider CT of head and/or a lumbar puncture as secondary diagnostic tests.



Further radiographic testing may be determined based on clinical suspicion (i.e., MRI brain, MR/CT angiogram/venogram or catheter angiography).



# Take home messages: treatment priorities

---



Address emergency treatments **prior** to aggressive pain management (osmotherapy, neurosurgical consultation, management of hydrocephalus, etc.).



Avoid excessive analgesics or sedatives that may confound an examination.



Avoid opioids use





# Take home messages: prognosis at a glance

---



Primary headaches have a benign prognosis although uncontrolled chronic pain may lead to disability.



Prognosis of secondary headaches is dependent on etiology, available treatments, and any associated neurologic complications.



Early identification of a secondary cause of headache may improve outcomes, particularly in cases of aneurysmal subarachnoid hemorrhage and acute bacterial meningitis.

GRAZIE PER L'ATTENZIONE

THANK YOU!



International  
Headache Society

